

**Case Report****Myoepithelial carcinoma of the male breast: a rare case report**

Mohd Athar^{1*}, Ashish Kumar Chaudhary¹, S Kala¹, Manoj Srivastava², Lubna Khan³,
Chaynika Kala³, Vivek Singh¹, Vardan Pandey¹

¹Department of General Surgery, GSVM Medical College Kanpur, UP, India

²Department of Oncosurgery, KGMU, Lucknow, UP, India

³Department of Pathology, GSVM Medical College Kanpur, UP, India

(Received 01 October 2016 and accepted 13 November 2016)

ABSTRACT: Myoepithelial carcinoma (malignant myoepithelioma) of the breast is a rare entity and in the male breast it is even rarer. Two cases of benign myoepithelioma in the male breast have been reported so far. Here we report, probably the first case of Myoepithelial carcinoma in a male breast with clinical features mimicking locally advanced breast carcinoma, together with illustration of pathological finding, microscopic appearance and management.

KEY WORDS: *Myoepithelial carcinoma; Modified radical mastectomy; Chemotherapy*

INTRODUCTION

Myoepithelial carcinoma of the breast remains a very rarely reported phenomenon, with only 30 cases reported in literature, that too only in females. Its incidence in the male breast is still rare and no case has been reported in the literature so far. This is a lesion mainly composed of malignant myoepithelial cells. Although histological, immunohistochemical and even ultrastructural features have been well described. Its definite diagnosis based on cytology is still difficult.

CASE DETAILS

A 62-year-old male presented with a painless swelling in the right breast of two-year duration with progressive increase in size and retraction of the nipple for last five months. Clinical examination revealed a hard nodular swelling in the right breast in the subareolar region with retraction of the nipple and skin involvement without palpable axillary lymphadenopathy. Ultrasound examination revealed a round hypoechoic solid mass just below the nipple-areola complex of 20X20 mm size, suspicious of malignancy. FNAC

showed malignant cytology. The patient was evaluated further by chest X-rays and USG Abdomen which did not show any evidence of distant metastasis.

Since FNAC was suggestive of malignancy with skin involvement (T4), the patient was taken for surgery and Modified Radical Mastectomy was done. The patient received six cycles of adjuvant chemotherapy FEC regimen (5-fluorouracil, epirubicin, cyclophosphamide) followed by radiation to the chest wall.

Gross examination of the resected specimen showed a 20X20X15 mm solid mass with involvement of the nipple-areola complex (**Figure 1**). The mass appeared pale on cut-section with central areas of necrosis and an infiltrative growth pattern. Histopathological examination revealed group of cells composed of haphazard arrangement of a mixture of large epithelioid, plasmacytoid and spindle cells with increased nuclear cytoplasmic ratio, nuclear pleomorphism and several mitotic figures (**Figure 2**). The final impression of HPE was myoepithelial carcinoma of breast with no axillary lymph node metastasis. Histopathological diagnosis was further confirmed by immunohistochemistry. Immunohistochemistry revealed positive staining with S-100 protein, Vimentin, smooth muscle actin (SMA) and negative staining for Estrogen and Progesterone Receptors.

*Correspondence at: Assistant Professor, Department of General Surgery, GSVM Medical College Kanpur, UP, India; Email: atharonco92@yahoo.com

The patient is doing well and there is no evidence of local recurrence (**Figure 3**) as well as distant metastasis after six months of follow-up.

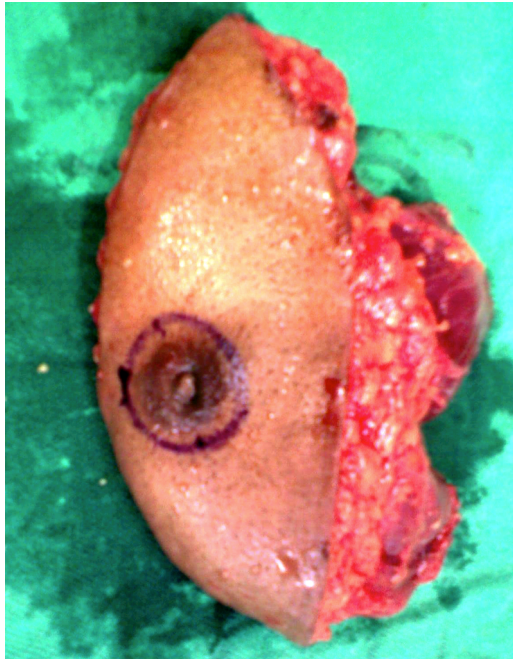


Figure 1: Resected breast tissue with the mass

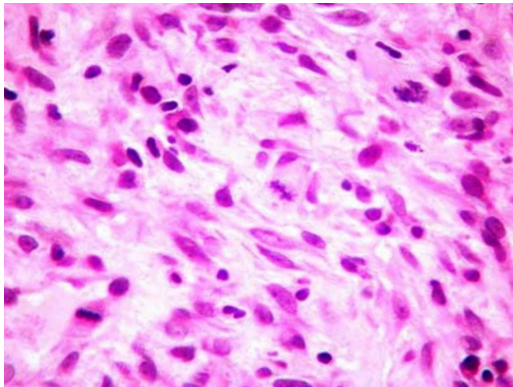


Figure 2: Histopathology of the tumor

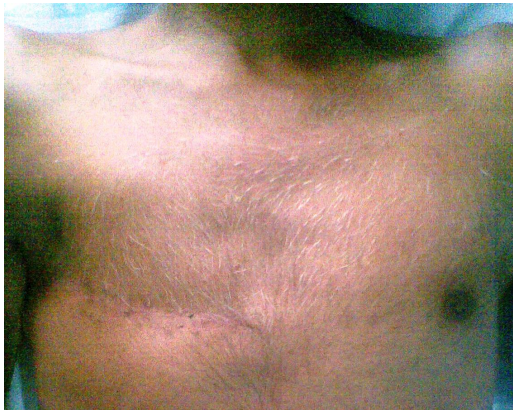

Figure 3: Healed scar after modified radical mastectomy

DISCUSSION

Myoepithelial carcinoma of the breast is extremely rare. A limited number of published reports have described myoepithelial carcinomas originating in the female breast¹. Its benign counterpart adenomyoepithelioma is also a rare tumor of the breast reported for the first time in 1970². Malignancy may arise either through malignant transformation of one or both the components of adenomyoepithelioma of the breast.

These tumors have been reported in women, ranging in age from 26 to 76 years with tumor size varying from 1 to 15 cm³. Clinically they present as a progressively enlarging, palpable, non-tender, laterally located mass⁴. This case of myoepithelial carcinoma is probably the first case, occurring in a 62 year male, presenting with a slowly increasing centrally located nodular painless swelling in the right breast with retraction of the nipple and skin involvement.

Metastases from myoepithelial carcinoma are described and usually they are hematogenous rather than lymphatic and they also appear to be restricted to cases of primary tumors with size greater than 2cm⁵⁻⁹.

Cytologically, it shows hypercellularity and haphazard cellular arrangement with cell population mainly composed of spindle, epithelioid, plasmacytoid and clear cells¹⁰. The cellular morphology includes nuclear pleomorphism with mitotic figures. Our case did not reveal a subpopulation of clear cells but showed the other three morphologies.

Immunohistochemically, cells stain positive for antibodies to cytokeratin 8 (CAM 5.2), actin, vimentin and cytokeratin 14 and negative for cytokeratin 18 and 19. Under electron microscopy, well-formed desmosomes and hemidesmosomes together with pinocytotic vesicles, plentiful rough endoplasmic reticulum and 6 nanometer microfilaments are seen¹¹. Benign adenomyoepithelial lesions variably express hormonal receptors in the epithelial component where as myoepithelial carcinomas typically are completely negative for hormone receptors¹². Our case also showed positive staining with S-100 protein, vimentin, SMA and negative for Estrogen and Progesterone Receptors.

The radiological findings of myoepithelial carcinomas are usually specific¹³. In our case both mammography and sonography showed features suggestive of malignancy such as ill-defined margins, distortion of breast parenchyma with distal acoustic shadowing.

Myoepithelial carcinomas in female breasts are treated mainly by wide local excision, lymph node dissection and adjuvant chemo-radiotherapy¹⁴.

This tumor is prone to local recurrence after surgery. The best predictor of local recurrence is an

initial close margin of excision. If the excision margin is close or having tumor infiltration (positive margin), re-excision is advised to gain adequate margin.

Myoepithelial carcinoma of the breast adopts an aggressive clinical course with an outcome comparable to poorly differentiated adenocarcinoma of the breast. Two and five year survival is 88% and 55% respectively¹⁵.

The response to chemotherapy and radiotherapy is unknown.

CONCLUSION

Myoepithelial carcinoma of the breast is a rare tumor, which should be suspected, in the differential diagnosis of solid breast lesions. Myoepithelial carcinoma is difficult to diagnose on cytology and core biopsy may be more accurate. Histological differential diagnosis includes spindle cell carcinoma (negative for myoepithelial marker), fibromatosis (positive for beta-catenin) and myofibroblastic lesion (no dominant nodule and keratin negative). Because of the potential for local recurrence following surgery and possibility of hematogenous rather than lymphatic metastasis, myoepithelial carcinoma should be treated like other malignant tumors of breast.

REFERENCES

1. Liao KC, Lee WY, Chen MJ. Myoepithelial carcinoma: a rare neoplasm of the breast. *Breast Care*. 2010;5(4):246-9.
2. Hamperl H. The myoepithelia (myoepithelial cells). Normal state; regressive changes; hyperplasia; tumors. *Curr Top Pathol*. 1970;53:161-220.
3. Michal M, Baumruk L, Burger J, Manhalova M. Adenomyoepithelioma of the breast with undifferentiated carcinoma component. *Histopathology*. 1994;2:274-6.
4. Tavassoli FA. Myoepithelial lesions of the breast. Myoepitheliosis, adenomyoepithelioma, and myoepithelial carcinoma. *Am J Surg Pathol*. 1991;15:554-68.
5. Ahmed AA, Heller DS. Malignant adenomyoepithelioma of the breast with malignant proliferation of epithelial and myoepithelial elements: a case report and review of the literature. *Arch Pathol Lab Med*. 2000;124:632-6.
6. Kihara M, Yokomise H, Irie A, Kobayashi S, et al. Malignant adenomyoepithelioma of the breast with lung metastases: report of a case. *Surg Today*. 2001;31:899-903.
7. Takahashi II, Tashiro H, Wakasugi K, Onohara T, et al. Malignant adenomyoepithelioma of the breast: a case with distant metastases. *Breast Cancer*. 1999; 6:73-7.
8. Bult P, Verwiel JM, Wobbles T, Kooy-Smits MM, et al. Malignant adenomyoepithelioma of the breast with metastasis in the thyroid gland 12 years after excision of the primary tumor. Case report and review of the literature. *Virchows Arch*. 2000;436:158-66.
9. Chen PC, Chen CK, Nicastrì AD, Wait RB. Myoepithelial carcinoma of the breast with distant metastasis and accompanied by adenomyoepitheliomas. *Histopathology*. 1994;24:543-8.
10. Darvishian F, Lin O. Myoepithelial cell-rich neoplasms: cytologic features of benign and malignant lesions. *Cancer*. 2004;102:355-61.
11. Lakhani SR, O'Hare MJ, Monaghan P, Winehouse J, et al. Malignant myoepithelioma (myoepithelial carcinoma) of the breast: a detailed cytokeratin study. *J Clin Pathol*. 1995;48:164-7.
12. Lakhani S, Ellis I, Schnitt S, Tan P, Van de Vijver M. WHO classification of tumors of the breast. IARC Press, Lyon, France. 2012.
13. Howlett DC, Mason CH, Biswas S, Sangle PD, et al. Adenomyoepithelioma of the breast: spectrum of disease with associated imaging and pathology. *AJR Am J Roentgenol*. 2003;180(3):799-803.
14. Noronha V, Cooper DL, Higgins SA, Murren JR, et al. Metastatic myoepithelial carcinoma of the vulva treated with carboplatin and paclitaxel. *Lancet Oncology*. 2006;7(3):270-1.
15. Behranwala KA, Nasiri N, A'Hern R, Gui GP. Clinical presentation and long-term outcome of pure myoepithelial carcinoma of the breast. *Eur J Surg Oncol*. 2004;30(4):357-61.