



Case Report

A case of fibrolipomatous hamartoma of the median nerve with macrodactyly

M N Suma*[¶], Padmini Jeyachandran** and Sathish Arakeri***

*Assistant Professor, **Professor, ***Resident, Department of Pathology, MVJ Medical College and Research Hospital, Dandupalya, Bangalore (Karnataka), India

(Received 27 July 2011 and accepted 25 September 2011)

ABSTRACT: Fibrolipomatous hamartoma of nerve is a tumor-like lipomatous process principally affecting young persons. The median nerve is most commonly involved. The lesion is characterized by a soft slowly growing mass, surrounding and infiltrating major nerves and their branches. It may cause symptoms of compression neuropathy and is associated with macrodactyly in one third of cases. Here, we present a case of Fibrolipomatous hamartoma of nerve in the wrist of a young man arising from median nerve. Debulking of the tumour was performed.

KEY WORDS: *Fibrolipomatous hamartoma; Macrodactyly; Median nerve*

INTRODUCTION

Fibrolipomatous hamartoma of nerve is a tumor-like lipomatous process that involves principally volar aspects of the hands, wrists and forearms of young persons¹. It usually manifests as a soft slowly growing mass consisting of proliferating fibrofatty tissue surrounding and infiltrating major nerves and their branches^{1,3}. About one third of neural fibrolipomas are associated with macrodactyly^{1,3,4}. The lesion is almost always seen during the first three decades of life, usually presenting with increasing pain, diminished sensation or paresthesia associated with a gradually enlarging mass causing compression neuropathy¹. Males are more often affected than females. There may be a genetic predisposition, but there is no history of any hereditary disorder¹. At operation, the lesion presents as a soft gray-yellow fusiform mass that has diffusely infiltrated large nerves¹. The encapsulated type tends to occur in the fourth and fifth decades, with predominance in women. The diffusely infiltrative type arises in a younger age group, with no sexual predominance and is commonly seen in the median nerve.

CASE DETAILS

A 16-year-old man presented with enlarged left index finger and a soft tissue linear swelling in the left wrist extending to the palm. This problem started at the age of two and had progressed gradually for the past three years. He did not complain of neurologic symptoms like pain and paresthesia. Physical examination revealed a soft tissue mass in the left wrist extending to the palm with enlarged left index finger (**Figure 1**). Overlying skin was normal. There was no local rise in temperature. Patient could move the fingers but some restriction of movement was noted at the distal interphalangeal joint of the left index finger. There were no alterations in sensation in the fingers. It was non-tender, soft in consistency and was non-compressible.



Figure 1: Macrodactyly of left Index finger

[¶]**Correspondence at:** Department of Pathology, MVJ Medical College and Research Hospital, NH4, Kolathur post, Dandupalya, Bangalore (Karnataka), India; Cell: +919 945206945; Email: sumasheshuvision2000@yahoo.co.in

Under general anaesthesia, skin was incised followed by incision of flexor retinaculum. The median nerve was found to be enlarged and tortuous from the level of the carpal tunnel (**Figure 2**). Swelling was prominently visible on both sides of flexor retinaculum. The nerve was insinuated with fibrous tissue and fat. The carpal tunnel was opened and debulking of the tumour was performed. Grossly, the tumour appeared pink-yellow in colour.

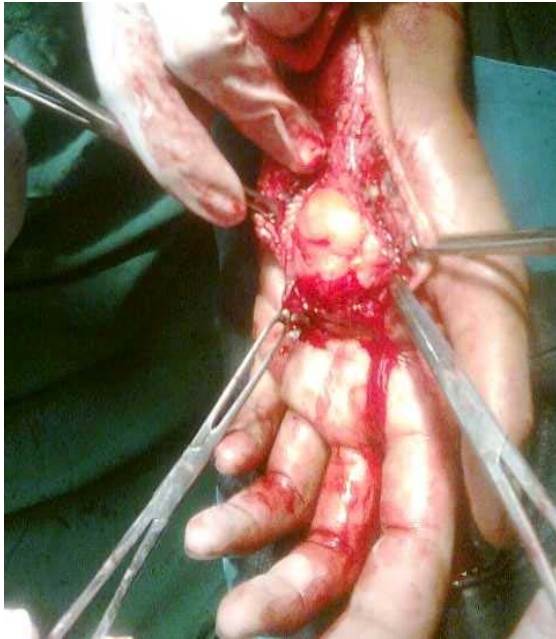

Figure 2: The mass as revealed at surgery

Histological sections of the lesion revealed atrophic nerve bundles with some of them showing perineural fibrosis (**Figure 3**).

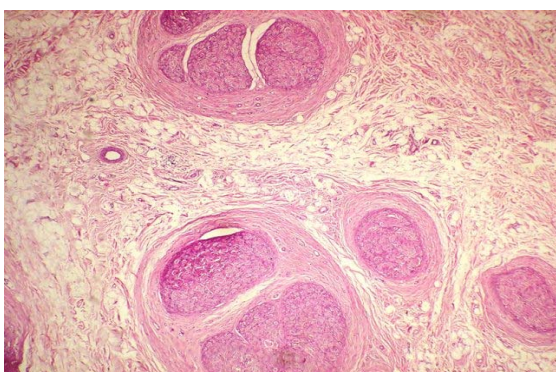


Figure 3: Microscopic appearance of transverse section of nerve bundles showing atrophy and perineural fibrosis H & E X10

The nerve bundles were intervened by increased amount of fibrofatty tissue (**Figure 4**). There was no postoperative neurological deficit.

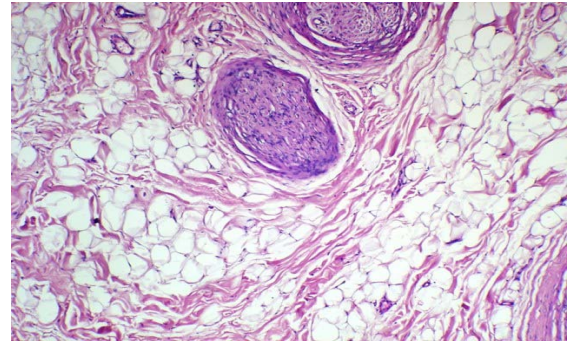


Figure 4: Nerve bundles intervened by fatty tissue H & E X40

DISCUSSION

Fibrolipomatous hamartoma is a rare benign lesion. Other terms applied to this condition include fibrolipomatous nerve enlargement, lipofibromatous hamartoma of nerves and neurolipomatosis⁵. About 1/3rd of neural fibrolipomas are associated with overgrowth of bone and macrodactyly of the digits innervated by the affected nerve.

Patients with fibrolipomatous hamartoma typically present in the first three decades of life, with signs and symptoms associated with nerve compression in the distribution of the affected nerve. There may also be some loss of strength. There is usually a long history of a painless mass since childhood⁶. Men and women are equally affected and there is no familial predisposition^{7,8}. However females predominate when the lesion is associated with macrodactyly. The upper extremity is involved in 78% to 96% of patients, and there is a marked predilection for the median nerve. In 27% to 67% of cases, fibrolipomatous hamartoma is associated with macrodystrophica lipomatosa^{3,9}. The reason for the predilection for the median nerve is not certain. However, the median nerve may easily become symptomatic due to encroachment of the flexor retinaculum.

Unlike most cases in the literature, our patient was a male, with a painless mass along with macrodactyly of left index finger. As with all neoplasms, the exact etiology of lipomata is unknown^{2,8}. Some researchers consider fibrolipomatous hamartoma to be a congenital tumour⁶ while others believe that it is incited to grow by nerve irritation, inflammation, or prior trauma¹⁰.

Histologically, perineural and endoneural fibrosis cause thickening of the neural fascicles. The interfascicular connective tissue is infiltrated by mature fat cells⁶. The perineural and endoneural fibrosis account for the low signal intensity of the thickened nerve fascicles, which appear as serpentine structures longitudinally oriented along the nerve. In this patient, the neural fascicles were evenly interspersed by fat at the level of the carpal

tunnel and and distal to it. The differential diagnoses of a median nerve mass include intraneural lipoma, ganglion cyst, traumatic neuroma, schwannoma, tenosynovitis, and vascular malformation. The presence of mature fat within the nerve virtually excludes the above possibilities. Conventional treatment involves carpal tunnel decompression by excising the flexor retinaculum and transverse carpal ligament. This procedure has resulted in clinical improvement in 60% of patients in one study. Debulking of the tumor can also be done. For complete resection, both satisfactory results and catastrophic motor and sensory deficit have been reported. In our case, excision of the swelling was done and did not result in any sensory or motor deficit on follow up.

CONCLUSION

In conclusion, fibrolipomatous hamartoma is a rare benign tumor that most commonly affects the median nerve. It may or may not present with macrodactyly. Final diagnosis can be achieved by histopathology. As the presentation is unique and treatment is controversial, this case is reported.

REFERENCES

1. Weiss S, Goldblum JR. Enzinger and Weiss's soft tissue tumors. 4th ed. St.Louis: Mosby; 2001;617-9.
2. Akisue T, Matsumoto K, Yamamoto T, et al. Neural fibrolipoma of the superficial peroneal nerve in the ankle: a case report with immunohistochemical analysis. *Pathol Int.* 2002 Nov;52(11):730-3.
3. Silverman TA, Enzinger FM. Fibrolipomatous hamartoma of nerve. A clinicopathologic analysis of 26 cases. *Am J Surg Pathol.* 1985 Jan;9(1):7-14.
4. Razzaghi A, Anastakis DJ. Lipofibromatous hamartoma: review of early diagnosis and treatment. *Can J Surg.* 2005 Oct;48(5):394-9.
5. Toms AP, Anastakis D, Bleakney RR, et al. Lipofibromatous hamartoma of the upper extremity: a review of the radiologic findings for 15 patients. *AJR Am J Roentgenol.* 2006 Mar;186(3):805-11.
6. Cavallaro MC, Taylor JA, Gorman JD, et al. Imaging findings in a patient with fibrolipomatous hamartoma of the median nerve. *AJR Am J Roentgenol.* 1993 Oct;161(4):837-8.
7. Bick EM. Lipoma of the extremities. *Ann Surg.* 1936 Jul;104(1):139-43.
8. Chiao HC, Marks KE, Bauer TW, et al. Intraneural lipoma of the sciatic nerve. *Clin Orthop Relat Res.* 1987 Aug;(221):267-71.
9. Amadio PC, Reiman HM, Dobyns JH. Lipofibromatous hamartoma of nerve. *J Hand Surg.* 1988 Jan;13(1):67-75.
10. Marom EM, Helms CA. Fibrolipomatous hamartoma: pathognomonic on MR imaging. *Skeletal Radiol.* 1999 May;28(5):260-4.